

Mutations in *LAMB1* Cause Cobblestone Brain Malformation without Muscular or Ocular Abnormalities

Farid Radmanesh,^{1,2,12} Ahmet Okay Caglayan,^{3,12} Jennifer L. Silhavy,^{1,2} Cahide Yilmaz,⁴ Vincent Cantagrel,^{1,2} Tarek Omar,⁵ Başak Rosti,^{1,2} Hande Kaymakcalan,⁶ Stacey Gabriel,⁷ Mingfeng Li,⁸ Nenad Šestan,⁸ Kaya Bilguvar,³ William B. Dobyns,^{9,10} Maha S. Zaki,¹¹ Murat Gunel,^{3,*} and Joseph G. Gleeson^{1,2,*}

Cobblestone brain malformation (COB) is a neuronal migration disorder characterized by protrusions of neurons beyond the first cortical layer at the pial surface of the brain. It is usually seen in association with dystroglycanopathy types of congenital muscular dystrophies (CMDs) and ocular abnormalities termed muscle-eye-brain disease. Here we report homozygous deleterious mutations in *LAMB1*, encoding laminin subunit beta-1, in two families with autosomal-recessive COB. Affected individuals displayed a constellation of brain malformations including cortical gyral and white-matter signal abnormalities, severe cerebellar dysplasia, brainstem hypoplasia, and occipital encephalocele, but they had less apparent ocular or muscular abnormalities than are typically observed in COB. *LAMB1* is localized to the pial basement membrane, suggesting that defective connection between radial glial cells and the pial surface mediated by *LAMB1* leads to this malformation.

The cerebral cortex is generated through proliferation of radial glial cells residing in the ventricular zone, migration of postmitotic neurons toward the pial surface, and organization of the laminar architecture with six neuronal layers.¹ Radial glial cells play a central role in cerebral cortical development, where they act both as the proliferative unit of the cerebral cortex and a scaffold for neurons migrating toward the pial surface.² The basement membrane/glia limitans (BM/GL) is located immediately below the pia matter and serves as an anchor point for the endfeet of radial glial cells and as a physical barrier to migrating neurons.³ Mutations in genes encoding BM constituents,^{4–6} those encoding cellular receptors that mediate interactions between cells and the extracellular matrix, or those encoding downstream effectors of such interactions^{7–9} have been shown to disrupt BM integrity and result in disorganized cortical lamination.

Cobblestone brain malformation (COB, originally referred to as lissencephaly type 2) is characterized by cortical dysplasia and aberrant neuroglial migration through breaches in the pial BM/GL into the subarachnoid space;^{10,11} the result is neuronal ectopia that produce an irregular “lumpy-bumpy” appearance.^{12,13} COB is typically observed in α -dystroglycanopathy types of congenital muscular dystrophies (CMDs), which are associated with various ocular abnormalities, delineating the spectrum of muscle-eye-brain disease (MIM 236670).¹⁴ However, it has also been reported as an isolated entity¹⁵ or in conjunc-

tion with minimal muscular abnormalities,¹⁶ reflecting genetic and clinical heterogeneity of the disorder. In fact, genetic studies have failed to identify a mutated gene in individuals with these *forme fruste* presentations.^{17,18} Here we report that mutations in *LAMB1*, encoding laminin subunit beta-1, are associated with COB with variable muscular or ocular abnormalities. Although *LAMB1* is expressed in skeletal muscle,¹⁹ our subjects did not have elevated creatine phosphokinase, suggesting *LAMB1* mutations as a cause for the muscle-sparing form of CMD.

We recruited two consanguineous families from Egypt and Turkey and report on a total of four affected members (Figure 1). In family 520, the first-cousin parents had three children with severely delayed developmental milestones, increased head circumference, and posterior encephalocele (Figure S1, available online). Symptomatic hydrocephalus had been present in all three siblings since birth and required shunt placement in the second child. Brain magnetic resonance imaging (MRI) revealed COB, evidenced by abnormal cortical gyri and sulci, dramatic white-matter signal abnormalities, and brainstem and cerebellar hypoplasia (Figure 2). Cortical gyration in the anterior forebrain regions was relatively preserved in comparison with that in the posterior regions on axial MRI sections, suggesting a posterior-anterior gradient. There was diffuse abnormal white-matter signal intensity and subcortical band-like gray matter lying approximately 1 cm below the cortex. The cortex was moderately thick

¹Neurogenetics Laboratory, Department of Neurosciences, University of California, San Diego, CA 92093, USA; ²Howard Hughes Medical Institute; ³Yale Program on Neurogenetics, Departments of Neurosurgery, Neurobiology and Genetics, Yale University, School of Medicine, New Haven, Connecticut 06510, USA; ⁴Department of Pediatrics, Division of Pediatric Neurology, School of Medicine, Mustafa Kemal University, Hatay 31000, Turkey; ⁵Department of Pediatrics and Pediatric Neurology, School of Medicine, Alexandria University, Alexandria 21558, Egypt; ⁶Department of Genetics and Bioinformatics, Bahcesehir University, Istanbul 34353 Turkey; ⁷Broad Institute of Harvard and Massachusetts Institute of Technology, Cambridge, MA 02142, USA; ⁸Department of Neurobiology, Kavli Institute of Neuroscience, Yale University, School of Medicine, New Haven, CT 06510, USA; ⁹Departments of Pediatrics and Neurology, University of Washington, Seattle, WA 98195, USA; ¹⁰Center for Integrative Brain Research, Seattle Children's Research Institute, Seattle, WA 98101, USA; ¹¹Clinical Genetics Department, Human Genetics and Genome Research Division, National Research Centre, Cairo, 12311, Egypt

¹²These authors contributed equally to this work

*Correspondence: murat.gunel@yale.edu (M.G.), jogleeson@ucsd.edu (J.G.G.)

<http://dx.doi.org/10.1016/j.ajhg.2013.02.005>. ©2013 by The American Society of Human Genetics. All rights reserved.

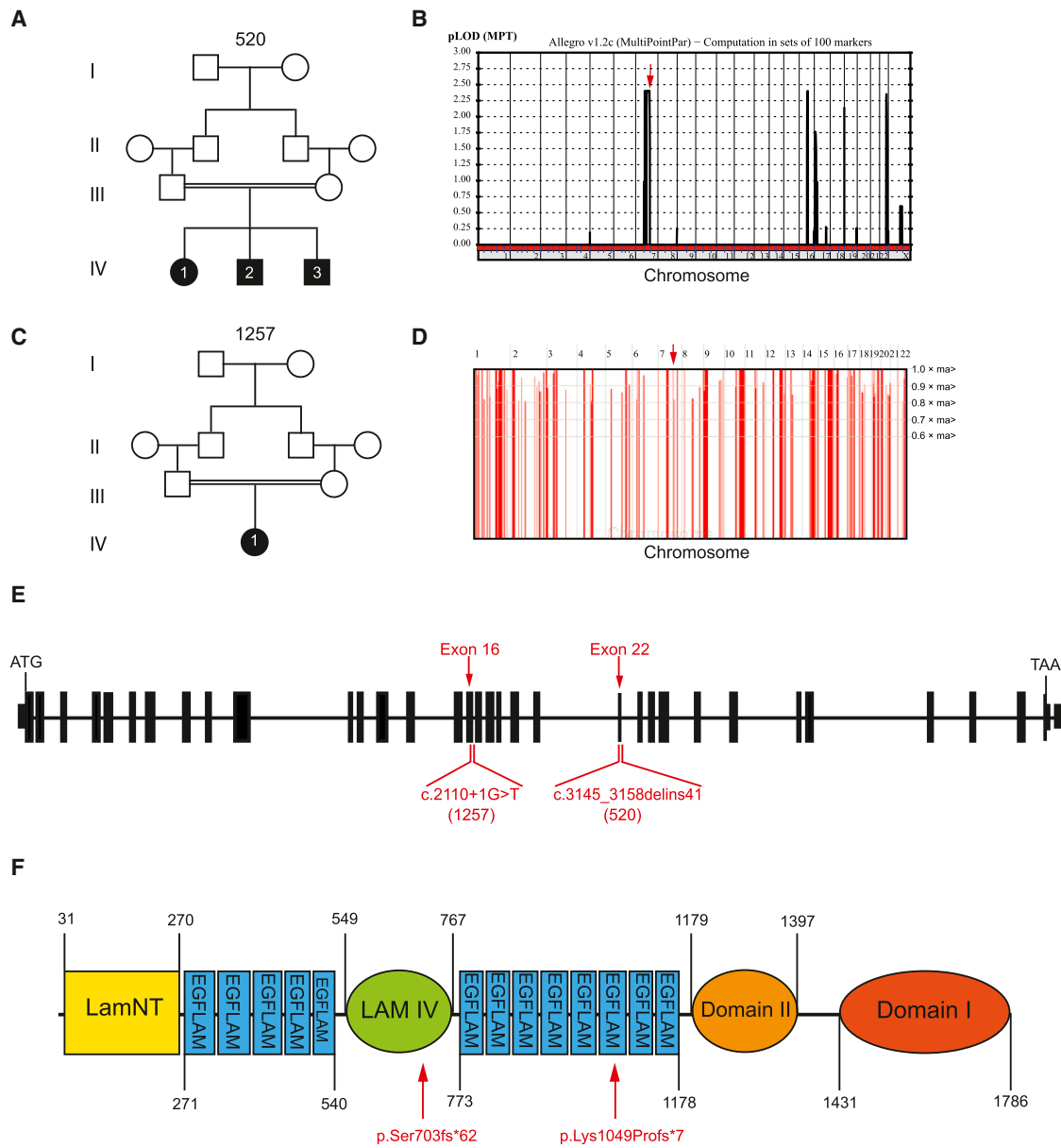


Figure 1. Mutations in *LAMB1* Lead to Cobblestone Brain Malformation

(A and C) Family pedigrees showing first-cousin marriages and a total of four affected children. Filled boxes represent affected individuals.
 (B) Whole-genome linkage analysis of family 520. Chromosomal position (x axis) and multipoint LOD scores (y axis) including a positive LOD score (~2.3) on chromosome 7 (red arrow) are shown.
 (D) Homozygosity plot for family 1257. Red bars represent stretches of homozygosity above a threshold of 3 cM. x axis: chromosomal position. y axis: degree of homozygosity. An arrow points to the homozygous interval containing *LAMB1*.
 (E and F) Schematic structure of *LAMB1*, the encoded protein, position of mutations, and corresponding family number in parentheses. Abbreviations are as follows: LamNT, Laminin N-terminal; LAM IV, Laminin IV type B; EGFLAM, Laminin Epidermal Growth Factor-like domain.

(~1 cm) and was more pronounced in temporal, parietal, and occipital regions. Deep in the inner cortical surface and separated from the cortex by a layer of white matter, contiguous nodules of gray matter left a thin beaded laminar heterotopia (most evident in subject 520-IV-3), the type of irregular heterotopia seen in other CMDs.²⁰ There was myelination disruption in subcortical “U” fibers in a pattern typical of COB, as well as delayed myelination in the deep and periventricular white matter. There was

also hypoplasia of the brainstem, cerebellar hemispheres, and vermis, as often observed in CMDs.²¹ The findings were most consistent with COB type A (the most severe form) according to a recent classification,¹¹ especially given the presence of encephalocele. Considering the classical association of COB and CMDs, we evaluated these subjects for muscular and ocular manifestations but identified no relevant abnormality (Table S1). They had normal creatine phosphokinase (CPK), electromyography,

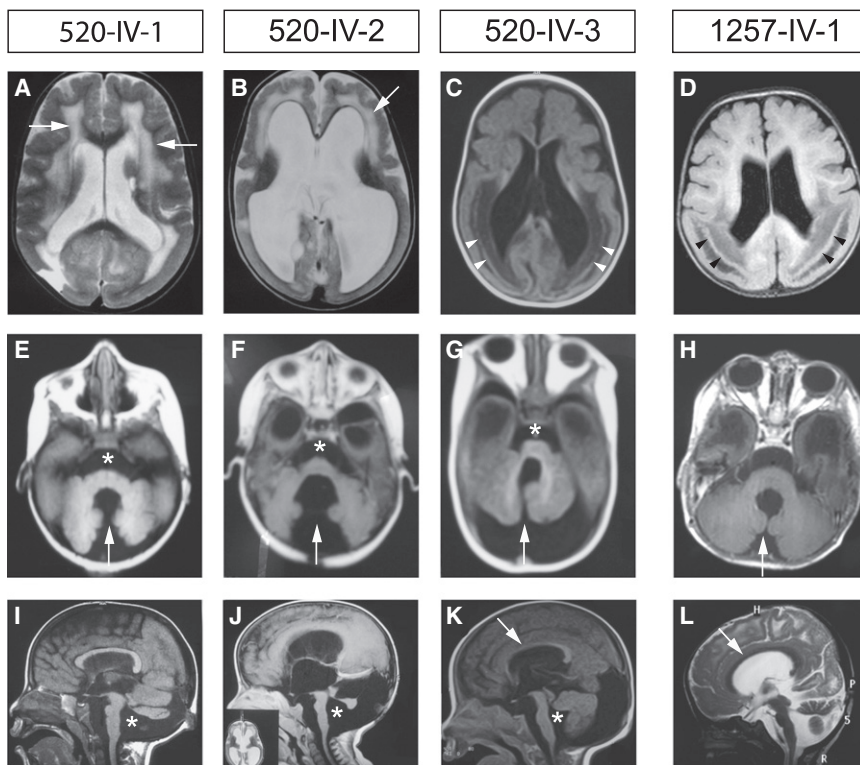


Figure 2. Brain MRI in Individuals with *LAMB1* Mutations

Brain MRI revealing (A–D) cobblestone malformation (COB), white-matter signal abnormality (arrows), an irregular layer of ectopic neurons (arrowheads), (E–H) cerebellar hemisphere and vermal hypoplasia (arrows), brain-stem hypoplasia (asterisk), (I–K) brain-stem hypoplasia (asterisk), and corpus-callosum hypoplasia (arrow).

and nerve conduction studies and no overt signs of amyotrophy or weakness, so muscle biopsy was not pursued. Ophthalmology assessments with indirect fundoscopy showed diffuse minor optic atrophy in the two older siblings but not in the youngest one (520-IV-3).

In order to identify the genetic cause for this condition, we performed whole-exome sequencing on the middle child in the family.²² This study was performed in accordance with the ethical standards set by our institutional review boards, and we obtained informed consent from each individual participating in this study. We performed segregation analysis for all unique and conserved variants via Sanger sequencing of PCR products that we amplified by using genomic DNA of all subjects and the parents. These studies led to the identification of a homozygous deletion of 14 bp and an insertion of 41 bp (c.3145_3158 delins41) in *LAMB1* (laminin subunit beta-1; Refseq accession number NM_002291.1 [MIM 150240]). This deletion and insertion resulted in a frameshift and premature stop (p.Lys1049Profs*7). The insertion was a triplication of a 19 bp fragment of the gene (c.3159_3177[3]), resulting in the deletion of 14 bases and the insertion of 14 bases and suggesting an inverted repeat-mediated mechanism.²³ The mutation was located in exon 22, encoding a laminin epidermal-growth-factor-like domain (EGFLAM) of the protein (Figures 1E–1F; see also Figure S2). Genome-wide linkage analysis with Illumina linkage map IVb²⁴ suggested that a locus on chromosome 7q22 carried the mutation with a multipoint logarithm of odds (LOD) score of ~2.3 (Figure 1B). This mapping defined an interval of ~35.5 Mb between the markers rs1029847 and rs885993

and included *LAMB1*, supporting the result obtained through whole-exome sequencing. Whole-exome sequencing appropriately covered all genes located in the candidate intervals with highest LOD scores, and no other shared unique deleterious variants were encountered by exome sequencing.

The second family, numbered 1257, was ascertained in Turkey. The parents were first cousins and had a child with a phenotype similar to that of the affected individuals in family 520. They came to medical

attention during late gestation because of intrauterine hydrocephalus, and the infant ultimately required shunt placement at 8 months of age. She had seizures, severe developmental delay, and a persistently increased head circumference. Brain MRI revealed COB, band-like heterotopia with posterior predominance, and hydrocephalus (Figure 2), very similar to the appearance of brain MRIs in family 520. Whole-exome sequencing identified a homozygous variant at the first nucleotide of the splice donor site in intron 16 prior to exon 17 of *LAMB1* (c.2110+1G>T). This variant segregated in the family in a way consistent with a recessive mode of inheritance (Figure S3). The mutation is predicted to lead to failure of splicing from exon 16 to exon 17 and to result in a frameshift (p.Ser703fs*62). The variant occurred within a block of homozygosity between chromosome 7 base positions 107575806 and 108524461 (Figure 1D). All genes known to be mutated in CMD¹⁴ were well covered in these subjects, and no deleterious variant was found in any of these genes. Neither of the two mutations was observed in the dbSNP or 1000 Genomes databases or in our cohort of 100 Egyptian and 100 Turkish ethnically matched control subjects, and both were absent from our in-house whole-exome database of more than 2,000 subjects with neurodevelopmental conditions.

Laminins are the major secreted glycoproteins found in the basal lamina, where they influence cell proliferation, differentiation, migration, and adhesion.²⁵ They are cross-shaped heterotrimeric proteins containing an alpha-, beta-, and gamma-chain from the *LAMA*, *LAMB*, and *LAMC* families, respectively. These are constituted by

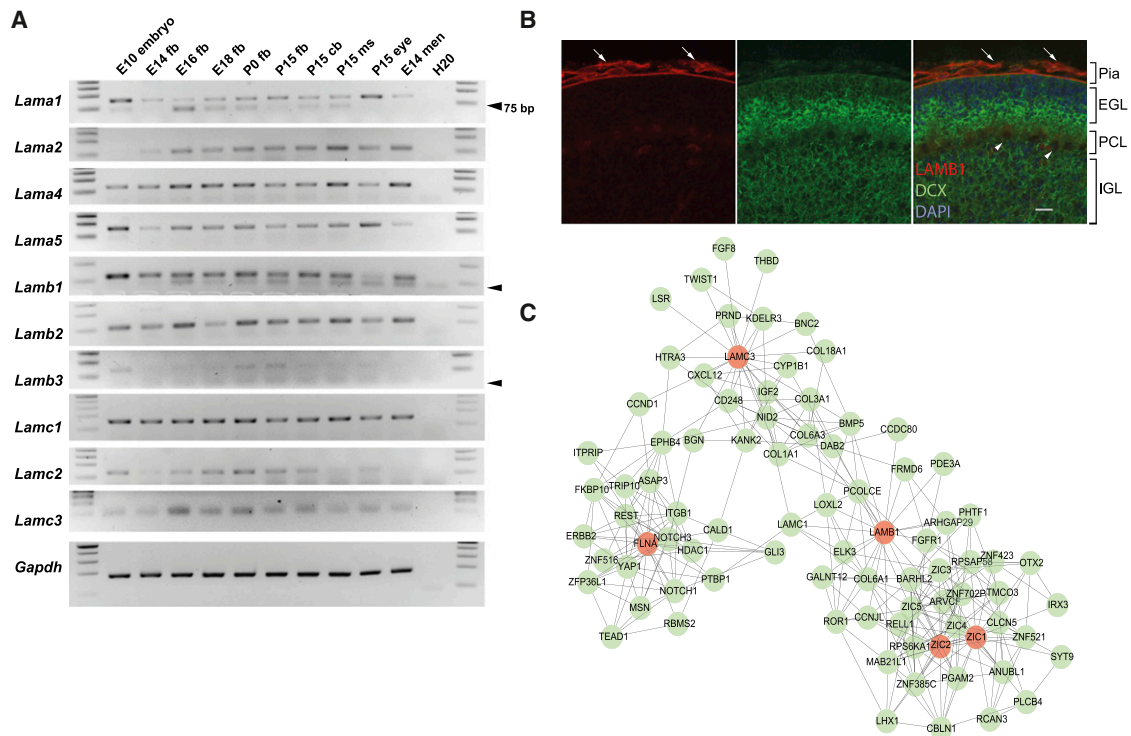


Figure 3. *LAMB1* Expression and Genetic Network

(A) RT-PCR of each known laminin gene in mouse tissue across development. Abbreviations are as follows: fb, forebrain; cb, cerebellum; ms, muscle; men, meninges; and H20, water control for PCR. Arrows indicate primer dimers.
 (B) Immunohistochemical staining of P7 wild-type mouse cerebellum with anti-doublecortin (DCX, green), anti-LAMB1 (red), and DAPI (blue). Arrows point to blood vessels over the pial BM. Arrowheads show Purkinje cells. Abbreviations are as follows: EGL, external granular layer; PCL, Purkinje cell layer; and IGL, internal granular layer. The scale bar represents 50 μ m.
 (C) Coexpression network analysis showing genes that are highly correlated (green circles). *LAMB1*, *LAMC3*, *ZIC1*, *ZIC2*, and *FLNA* are the brain malformation seed genes (red circles).

five, four, and three genes of each type, respectively, and contribute to at least 15 different combinations in mammals.¹⁹ Individual laminin subunits demonstrate specific spatial and temporal expression patterns.²⁶ Laminin subunit beta-1, encoded by *LAMB1*, is present in six of the 15 laminins²⁷ and is one of the earliest laminin subunits expressed during mammalian development at various sites, including the neuroectoderm.¹⁹ In the nervous system, laminins are thought to be involved in several processes, including neurite outgrowth, neural survival, and synapse formation and function.²⁷ However, in vivo study of specific laminin subunits in mammalian brain development has been hampered by early lethality of laminin-mutant mice.²⁵

We compared the expression of *Lamb1* with the expression of each of the other known *Lamb* genes. We profiled *Lamb1* expression in murine tissue from embryonic day 10 (E10) through postnatal day 15 (P15) by using RT-PCR and compared *Lamb1* transcripts with each of the other known laminin transcripts (Figure 3A). *Lamb1* showed relatively strong and ubiquitous expression in the whole E10 embryo, in E14, E16, P0, and F15 forebrain, and in P15 cerebellum and muscle. Expression in the eye globe was relatively lower than that in other tissues, but expression in embryonic meninges was strong. Mutation of

LAMB3 causes a specific skin defect known as epidermolysis bullosa (MIM 226650),²⁸ whereas mutations of *LAMB2* predominantly cause a kidney and eye disease known as Pierson syndrome (MIM 609049), which can include intellectual disabilities.²⁹ *Lamb1* was similar in tissue distribution to *Lamb2*, whereas *Lamb3* was relatively low in each tissue tested (skin was not tested).

Comparing expression of *Lamb1* with the *Lama* and *Lamc* families shows quite similar and broad distributions. *LAMA2* mutations in humans cause Merosin-deficient CMD (MIM 607855), which can include COB-like brain malformations,³⁰ and *Lama2* showed expression similar to that of *Lamb1*. In addition, we have demonstrated that recessive mutations in *LAMC3*, encoding laminin gamma-3, cause a highly specific occipital pachygyria (MIM 614115) phenotype characterized by cortical thickening and reduced gyration of the occipital lobe,³¹ and *Lamc3* shows widespread distribution similar to that of *Lamb1*. In fact, *Lamb2/Lamc3* compound-null mice exhibit severe disruptions in pial BM and cortical ectopias, features that resemble human cobblestone malformation.³²

Immunostaining of mouse brain at postnatal day 7 with LAMB1 antibodies demonstrated high levels in the cerebellar BM, consistent with the severe cerebellar phenotype we observed in our subjects (Figure 3B). Zebrafish *lamb1*

mutants have a disintegrated retinal inner limiting membrane and ectopias that protrude into the interstitial space between the retina and the lens.²⁵ These features are consistent with the cortical and cerebellar defects observed in these individuals but suggest that the role for *LAMB1* in the eye is not recapitulated in humans.

We next performed weighted gene coexpression analysis by using the human brain transcriptome,³³ which we visualized with Cytoscape to explore other genes highly correlated with *LAMB1* and genes causing similar brain malformations; such genes include *LAMC3*, *ZIC1*, *ZIC2*, and *FLNA* (Figure 3C). *Zic1* and *Zic2* are zinc-finger transcription factors that are critical for proliferation and maintenance of meningeal fibroblasts, and mutant mice show cortical lamination defects resembling COB.³⁴ In addition, heterozygous deletions of *ZIC1* and *ZIC4* in humans are associated with Dandy-Walker malformation (MIM 220200),³⁵ a severe cerebellar developmental defect. We found that *LAMB1* expression was correlated with expression of *ZIC1*, *ZIC2*, and genes encoding collagens and other laminins, suggesting a genetic network regulating BM function. Interestingly, *COL3A1* was identified at an intersection of *LAMB1* and *LAMC3*. *COL3A1* (MIM 606854) encodes a ligand for the receptor GPR56, and mutations in either gene lead to COB-like brain defects in mammals.^{6,36} Included in this network is *NID2*, encoding a known component of the BM,³⁷ and *COL1A1*, which is mutated in Ehlers-Danlos syndrome (MIM 130060) but also produces neocortical dyslamination in mice when mutated.³⁸ This correlated expression map suggests a gene network regulating interactions between radial glial cells and the BM.

COB and subcortical band heterotopia (SBH) are categorized as distinct abnormalities because of the shared genetic etiology of SBH with classic lissencephaly (type 1 lissencephaly, MIM [607432]). More recently, a study on the role of RhoA in the developing cerebral cortex has blurred this distinction.³⁹ RhoA is a small GTPase that mediates the linkage between cellular receptors of BM and the actin cytoskeleton. *RhoA* deletion from radial glial cells specifically causes failure of the cells to span the entire cortical thickness and results in COB and SBH in mice. Similarly, deletion of focal adhesion kinase, a downstream effector of RhoA, from glial cells and meningeal fibroblasts results in abnormalities characteristic for COB.⁷ These findings suggest that inadequate migration and migration past the pial surface could occur as a result of the same underlying genetic defect. The fact that our subjects share these similar features, including features of COB as well as SBH, supports this model.

All three affected individuals in family 520 had occipital encephalocele (OE), but the etiology of OE associated with COB is unclear. The major components of the pial BM are produced by meningeal cells,⁴⁰ and the dura mater contributes essential ossification signals to the overlying cephalic mesenchyme. The dura and arachnoid maters are composed of connective tissue, and therefore defects

in laminins could theoretically cause abnormalities in ossificatory signals and thereby protrusion of brain tissue through defects in the skull. Encephaloceles are known to accompany the severe forms of COB, but the mechanisms are unknown.^{41,42} Consistent with this, mutation in *COL18A1* in humans leads to Knobloch syndrome (MIM 267750), a recessive disorder that includes OE.⁴³ *COL18A1* appears adjacent to *LAMB1* and *LAMC3* on our coexpression map. Because laminins are known to associate with collagens, we hypothesize *LAMB1* might associate with *COL18A1* at the cephalic mesenchyme.

In summary, we describe loss-of-function mutations in *LAMB1* as a cause for COB in the absence of overt muscle or eye abnormalities. Aligning our data with the published data suggests a function for the encoded *LAMB1* at the BM, where it mediates both the integrity of the GL and the attachment of radial glial endfeet. As radial glia detach, the scaffolding mediating neuronal migration disintegrates, leading to subcortical heterotopia. At the same time, neurons can migrate past the GL, producing a cobblestone cortex. Further work will be required to determine the exact subunit constituents and genetic requirements of the basal lamina during brain development.

Supplemental Data

Supplemental Data include three figures and one table and can be found with this article online at <http://www.cell.com/AJHG/>.

Acknowledgments

We are grateful to the families for their participation in the study. We thank the Broad Institute (supported by the US National Human Genome Research Institute; grant U54HG003067 to E. Lander), the Yale Center for Mendelian Disorders; (grant U54HG006504 to R. Lifton, M. Gunel, M. Gerstein, and S. Mane) for sequencing support and analysis, J. Santini at the UCSD Microscopy Core for imaging (P30NS047101), the Yale Biomedical High Performance Computing Center for data analysis and storage, the Yale Program on Neurogenetics, the Yale Center for Human Genetics and Genomics, and Carsten G. Bönnemann (National Institute of Neurological Disorders and Stroke) for discussions. This work was supported by US National Institutes of Health (NIH) grant RC2NS070477 and the Gregory M. Kiez and Mehmet Kutman Foundation (M.G.), NIH grants U01MH081896 (to N.S.), R01NS048453, R01NS052455, and P01HD070494, the Simons Foundation Autism Research Initiative, and the Howard Hughes Medical Institute (to J.G.G.).

Received: October 11, 2012

Revised: November 5, 2012

Accepted: February 8, 2013

Published: March 7, 2013

Web Resources

The URLs for data presented herein are as follows:

Cytoscape, www.cytoscape.org

Human Brain Transcriptome database, <http://www.humanbraintranscriptome.org>

Online Mendelian Inheritance in Man (OMIM), <http://www.omim.org>
SeattleSeq Annotation, <http://gvs.gs.washington.edu>
UCSC Genome Browser, <http://www.genome.ucsc.edu>
Universal Protein Resource, <http://uniprot.org>

Accession Numbers

Exome data were deposited at dbGaP under accession number phs000288.v1.p1.

References

- Guerrini, R., and Parrini, E. (2010). Neuronal migration disorders. *Neurobiol. Dis.* 38, 154–166.
- Hansen, D.V., Lui, J.H., Parker, P.R., and Kriegstein, A.R. (2010). Neurogenic radial glia in the outer subventricular zone of human neocortex. *Nature* 464, 554–561.
- Siegenthaler, J.A., and Pleasure, S.J. (2011). We have got you 'covered': how the meninges control brain development. *Curr. Opin. Genet. Dev.* 21, 249–255.
- Labelle-Dumais, C., Dilworth, D.J., Harrington, E.P., de Leau, M., Lyons, D., Kabaeva, Z., Manzini, M.C., Dobyns, W.B., Walsh, C.A., Michele, D.E., and Gould, D.B. (2011). COL4A1 mutations cause ocular dysgenesis, neuronal localization defects, and myopathy in mice and Walker-Warburg syndrome in humans. *PLoS Genet.* 7, e1002062.
- Costell, M., Gustafsson, E., Aszódi, A., Mörgelin, M., Bloch, W., Hunziker, E., Addicks, K., Timpl, R., and Fässler, R. (1999). Perlecan maintains the integrity of cartilage and some basement membranes. *J. Cell Biol.* 147, 1109–1122.
- Luo, R., Jeong, S.J., Jin, Z., Strokes, N., Li, S., and Piao, X. (2011). G protein-coupled receptor 56 and collagen III, a receptor-ligand pair, regulates cortical development and lamination. *Proc. Natl. Acad. Sci. USA* 108, 12925–12930.
- Beggs, H.E., Schahin-Reed, D., Zang, K., Goebbels, S., Nave, K.A., Gorski, J., Jones, K.R., Sretavan, D., and Reichardt, L.F. (2003). FAK deficiency in cells contributing to the basal lamina results in cortical abnormalities resembling congenital muscular dystrophies. *Neuron* 40, 501–514.
- Georges-Labouesse, E., Mark, M., Messaddeq, N., and Gansmüller, A. (1998). Essential role of alpha 6 integrins in cortical and retinal lamination. *Curr. Biol.* 8, 983–986.
- Graus-Porta, D., Blaess, S., Senften, M., Littlewood-Evans, A., Damsky, C., Huang, Z., Orban, P., Klein, R., Schittny, J.C., and Müller, U. (2001). Beta1-class integrins regulate the development of laminae and folia in the cerebral and cerebellar cortex. *Neuron* 31, 367–379.
- Martin, P.T. (2005). The dystroglycanopathies: the new disorders of O-linked glycosylation. *Semin. Pediatr. Neurol.* 12, 152–158.
- Devisme, L., Bouchet, C., Gonzalès, M., Alanio, E., Bazin, A., Bessières, B., Bigi, N., Blanchet, P., Bonneau, D., Bonnières, M., et al. (2012). Cobblestone lissencephaly: neuropathological subtypes and correlations with genes of dystroglycanopathies. *Brain* 135, 469–482.
- Olson, E.C., and Walsh, C.A. (2002). Smooth, rough and upside-down neocortical development. *Curr. Opin. Genet. Dev.* 12, 320–327.
- Kerjan, G., and Gleeson, J.G. (2007). Genetic mechanisms underlying abnormal neuronal migration in classical lissencephaly. *Trends Genet.* 23, 623–630.
- Godfrey, C., Foley, A.R., Clement, E., and Muntoni, F. (2011). Dystroglycanopathies: coming into focus. *Curr. Opin. Genet. Dev.* 21, 278–285.
- Dobyns, W.B., Patton, M.A., Stratton, R.F., Mastrobattista, J.M., Blanton, S.H., and Northrup, H. (1996). Cobblestone lissencephaly with normal eyes and muscle. *Neuropediatrics* 27, 70–75.
- Okanishi, T., Ishikawa, T., Kobayashi, S., Ando, N., Nishino, I., Togari, H., and Nonaka, I. (2010). Bilateral occipital cortical dysplasia and white matter T2 hyperintensity with mild non-specific myopathy: two sibling cases. *Brain Dev.* 32, 342–346.
- Bouchet, C., Gonzales, M., Vuillaumier-Barrot, S., Devisme, L., Lebizec, C., Alanio, E., Bazin, A., Bessières-Grattagliano, B., Bigi, N., Blanchet, P., et al. (2007). Molecular heterogeneity in fetal forms of type II lissencephaly. *Hum. Mutat.* 28, 1020–1027.
- Mercuri, E., Messina, S., Bruno, C., Mora, M., Pegoraro, E., Comi, G.P., D'Amico, A., Aiello, C., Biancheri, R., Berardinelli, A., et al. (2009). Congenital muscular dystrophies with defective glycosylation of dystroglycan: a population study. *Neurology* 72, 1802–1809.
- Roediger, M., Miosge, N., and Gersdorff, N. (2010). Tissue distribution of the laminin beta1 and beta2 chain during embryonic and fetal human development. *J. Mol. Histol.* 41, 177–184.
- Jissendi-Tchofo, P., Kara, S., and Barkovich, A.J. (2009). Midbrain-hindbrain involvement in lissencephalies. *Neurology* 72, 410–418.
- Barkovich, A.J. (2012). Developmental disorders of the midbrain and hindbrain. *Front. Neuroanat.* 6, 7.
- Novarino, G., El-Fishawy, P., Kayserili, H., Meguid, N.A., Scott, E.M., Schroth, J., Silhavy, J.L., Kara, M., Khalil, R.O., Ben-Omran, T., et al. (2012). Mutations in BCKD-kinase lead to a potentially treatable form of autism with epilepsy. *Science* 338, 394–397.
- Carvalho, C.M., Ramocki, M.B., Pehlivan, D., Franco, L.M., Gonzaga-Jauregui, C., Fang, P., McCall, A., Pivnick, E.K., Hines-Dowell, S., Seaver, L.H., et al. (2011). Inverted genomic segments and complex triplication rearrangements are mediated by inverted repeats in the human genome. *Nat. Genet.* 43, 1074–1081.
- Murray, S.S., Oliphant, A., Shen, R., McBride, C., Steeke, R.J., Shannon, S.G., Rubano, T., Kermani, B.G., Fan, J.B., Chee, M.S., and Hansen, M.S. (2004). A highly informative SNP linkage panel for human genetic studies. *Nat. Methods* 1, 113–117.
- Lee, J., and Gross, J.M. (2007). Laminin beta1 and gamma1 containing laminins are essential for basement membrane integrity in the zebrafish eye. *Invest. Ophthalmol. Vis. Sci.* 48, 2483–2490.
- Sharif, K.A., Li, C., and Gudas, L.J. (2001). cis-acting DNA regulatory elements, including the retinoic acid response element, are required for tissue specific laminin B1 promoter/lacZ expression in transgenic mice. *Mech. Dev.* 103, 13–25.
- Sharif, K.A., Baker, H., and Gudas, L.J. (2004). Differential regulation of laminin b1 transgene expression in the neonatal and adult mouse brain. *Neuroscience* 126, 967–978.
- Pulkkinen, L., Christiano, A.M., Gerecke, D., Wagman, D.W., Burgeson, R.E., Pittelkow, M.R., and Uitto, J. (1994). A homozygous nonsense mutation in the beta 3 chain gene of laminin

- 5 (LAMB3) in Herlitz junctional epidermolysis bullosa. *Genomics* 24, 357–360.
29. Zenker, M., Aigner, T., Wendler, O., Tralau, T., Müntefering, H., Fenski, R., Pitz, S., Schumacher, V., Royer-Pokora, B., Wühl, E., et al. (2004). Human laminin beta2 deficiency causes congenital nephrosis with mesangial sclerosis and distinct eye abnormalities. *Hum. Mol. Genet.* 13, 2625–2632.
30. Geranmayeh, F., Clement, E., Feng, L.H., Sewry, C., Pagan, J., Mein, R., Abbs, S., Brueton, L., Childs, A.M., Jungbluth, H., et al. (2010). Genotype-phenotype correlation in a large population of muscular dystrophy patients with LAMA2 mutations. *Neuromuscul. Disord.* 20, 241–250.
31. Barak, T., Kwan, K.Y., Louvi, A., Demirbilek, V., Saygi, S., Tüysüz, B., Choi, M., Boyaci, H., Doerschner, K., Zhu, Y., et al. (2011). Recessive LAMC3 mutations cause malformations of occipital cortical development. *Nat. Genet.* 43, 590–594.
32. Radner, S., Banos, C., Bachay, G., Li, Y.N., Hunter, D.D., Brunken, W.J., and Yee, K.T. (2013). beta2 and gamma3 laminins are critical cortical basement membrane components: Ablation of Lamb2 and Lamc3 genes disrupts cortical lamination and produces dysplasia. *Dev. Neurobiol.* 73, 209–229.
33. Kang, H.J., Kawasawa, Y.I., Cheng, F., Zhu, Y., Xu, X., Li, M., Sousa, A.M., Pletikos, M., Meyer, K.A., Sedmak, G., et al. (2011). Spatio-temporal transcriptome of the human brain. *Nature* 478, 483–489.
34. Inoue, T., Ogawa, M., Mikoshiba, K., and Aruga, J. (2008). Zic deficiency in the cortical marginal zone and meninges results in cortical lamination defects resembling those in type II lissencephaly. *J. Neurosci.* 28, 4712–4725.
35. Grinberg, I., Northrup, H., Ardinger, H., Prasad, C., Dobyns, W.B., and Millen, K.J. (2004). Heterozygous deletion of the linked genes ZIC1 and ZIC4 is involved in Dandy-Walker malformation. *Nat. Genet.* 36, 1053–1055.
36. Bahi-Buisson, N., Poirier, K., Boddaert, N., Fallet-Bianco, C., Specchio, N., Bertini, E., Caglayan, O., Lascelles, K., Elie, C., Rambaud, J., et al. (2010). GPR56-related bilateral frontoparietal polymicrogyria: further evidence for an overlap with the cobblestone complex. *Brain* 133, 3194–3209.
37. Kohfeldt, E., Sasaki, T., Göhring, W., and Timpl, R. (1998). Nidogen-2: a new basement membrane protein with diverse binding properties. *J. Mol. Biol.* 282, 99–109.
38. Jeong, S.J., Li, S., Luo, R., Strokes, N., and Piao, X. (2012). Loss of Col3a1, the gene for Ehlers-Danlos syndrome type IV, results in neocortical dyslamination. *PLoS ONE* 7, e29767.
39. Cappello, S., Böhringer, C.R., Bergami, M., Conzelmann, K.K., Ghanem, A., Tomassy, G.S., Arlotta, P., Mainardi, M., Allegra, M., Caleo, M., et al. (2012). A radial glia-specific role of RhoA in double cortex formation. *Neuron* 73, 911–924.
40. Chen, Z.L., Haegeli, V., Yu, H., and Strickland, S. (2009). Cortical deficiency of laminin gamma1 impairs the AKT/GSK-3beta signaling pathway and leads to defects in neurite outgrowth and neuronal migration. *Dev. Biol.* 327, 158–168.
41. Brasseur-Daudruy, M., Vivier, P.H., Ickowicz, V., Eurin, D., and Verspyck, E. (2012). Walker-Warburg syndrome diagnosed by findings of typical ocular abnormalities on prenatal ultrasound. *Pediatr. Radiol.* 42, 488–490.
42. Vuillaumier-Barrot, S., Bouchet-Séraphin, C., Chelbi, M., Devisme, L., Quentin, S., Gazal, S., Laquerrière, A., Fallet-Bianco, C., Loget, P., Odent, S., et al. (2012). Identification of mutations in TMEM5 and ISPD as a cause of severe cobblestone lissencephaly. *Am. J. Hum. Genet.* 91, 1135–1143.
43. Sertié, A.L., Sossi, V., Camargo, A.A., Zatz, M., Brahe, C., and Passos-Bueno, M.R. (2000). Collagen XVIII, containing an endogenous inhibitor of angiogenesis and tumor growth, plays a critical role in the maintenance of retinal structure and in neural tube closure (Knobloch syndrome). *Hum. Mol. Genet.* 9, 2051–2058.